

Evaluation of mice's liver and kidney alterations caused by CPF with consumption of hesperidin

Malika J. Rizaeva¹, Salamat B. Ayapov², Jobir Akhmedov^{3*}, Okhunjon Rajabov⁴, Klara R. Dilmuradova⁵, Matlyuba I. Saidkarimova⁶, Matlyuba S. Mulhamedova⁷, Madina Ikramova⁸, Mirkomil Gudalov⁹, Farxod H. Shernazarov¹⁰

1. Assistant of the Department of Anesthesiology and Resuscitation, Children's Anesthesiology and Resuscitation, Bukhara State Medical Institute, Bukhara, Uzbekistan

2. Docent, Head of the Department of Art Science, Karakalpak State University, named after Berdak, Nukus, Republic of Karakalpakstan

3. Kimyo International University in Tashkent Shota Rustaveli Street 156, 100121, Tashkent, Uzbekistan

4. Assistant, Navoi State University of Mining and Technologies, Navoi, Uzbekistan

5. DSc, Professor of the Department of Pediatrics and Neonatology Faculty of Postgraduate Education of the Samarkand State Medical University, Samarkand, Uzbekistan

6. Associate professor, Tashkent State Technical University, Uzbekistan

7. Senior Teacher, Department of Pharmaceuticals and Chemistry, Faculty of Medicine, Alfraganus University, Tashkent, Uzbekistan

8. Assistant, Department of "Engineering Graphics and Design Theory," Tashkent Institute of Irrigation and Agricultural Mechanization Engineers, National Research University, Tashkent, Uzbekistan

9. Associate Professor, Jizzakh State Pedagogical University, Jizzakh, Uzbekistan

10. Candidate of Medical Sciences, Associate Professor, Gulistan State University, Gulistan, Uzbekistan

* Corresponding author's Email: j.akhmedov@kiut.uz

ABSTRACT

Chlorpyrifos (CPF) is identified as a hepatotoxic agent that detrimentally influences various organ systems. This research examined the hesperidin impacts and its underlying mechanisms on the deterioration of liver and renal tissue function resulting from CPF exposure. A total of fifteen C57 mice were separated into three experimental groups: CPF, Control, and CPF + hesperidin. The evaluations of serum SOD activity, alongside assessments of hepatic and renal function, were performed through enzyme level quantification and histopathological analysis. Post-CPF treatment, hepatic injury was marked by localized foci of coagulative necrosis, infiltration of inflammatory cells, and regenerative fibrosis. Conversely, the prescription of hesperidin caused a noticeable decrease in the inflammation. The protective effects of hesperidin may, at least partially, be attributed to its antioxidant and anti-inflammatory characteristics. Notably, BUN, SGOT, SGPT, and ALP concentrations were considerably diminished in the treatment cohort compared to the CPF. These findings suggest that CPF contributes to the manifestation of renal and hepatic lesions and underscore the importance of enzyme analysis in elucidating hepatotoxicity, which can be influenced by Hesperidin.

Keywords: Antioxidant, Chlorpyrifos, Liver, Kidney, Hesperidin.

Article type: Research Article.

INTRODUCTION

Pesticides play a crucial role in agricultural systems and public health strategies. They effectively manage agrarian pests, reduce food loss, and control disease vectors that pose risks to human and animal health. The ongoing growth of the global population has intensified the demand for increased food production, leading to a heightened dependence on pesticides (Blain 2011). Organophosphate pesticides (OPs), derived from phosphorus-based compounds such as phosphoric and phosphorothioic acids, are among the most commonly used. Despite being

used for over fifty years in pest control, the application of OPs has significantly risen following the ban on organochlorine pesticides. This rise is largely due to the relatively short environmental lifespan of OPs and their lower health risks compared to organochlorine pesticides. However, improper practices related to using, storing, transporting, applying, and disposing of pesticide residues can endanger non-target species. OPs can enter organisms through three main exposure pathways: oral, respiratory, and dermal (Mansukhani *et al.* 2024). Chlorpyrifos appears as white or colorless crystalline solids and is utilized to control a range of pests. It has been authorized for use in both agricultural and non-agricultural settings since 1965. Human exposure to this pesticide can occur through ingestion, inhalation, or skin contact with mucous membranes (Nandi *et al.* 2022). Consequently, chlorpyrifos is often detected in environmental samples, raising significant public health concerns. In Iran, the application of chlorpyrifos (CPF) in agricultural practices is prevalent, yet its residues on crops pose significant health risks to humans, as evidenced by numerous academic studies. CPF has been identified in various environmental contexts, such as surface waters, seawater, and precipitation (Kermani *et al.* 2021; Kaur & Kumar Sharma 2025). Current therapeutic strategies demonstrate limited effectiveness in halting or preventing the symptomatic progression of degenerative diseases, primarily focusing on symptom management rather than addressing underlying pathologies. This situation underscores the pressing need to develop alternative pharmacological agents to prevent and protect against these age-related disorders. Naturally occurring compounds offer promising avenues for managing the progression of such conditions. Aromatic plants constitute a significant category of herbal agents historically utilized for their protective properties. A different assortment of natural polyphenols, for instance, flavonoids, phenolic acids, and vitamins, has demonstrated significant health advantages for humans. Extensive research has validated the antioxidant and anti-inflammatory effects of these phytochemicals (Pyrzynska 2022; Yönden *et al.* 2022). Hesperidin is classified as a flavanone glycoside and primarily originates from citrus fruits, including lemons, sweet oranges (*Citrus sinensis*), and grapefruits. In addition to the *Citrus* genus, hesperidin can be extracted from a variety of other plant families, such as Fabaceae, Papilionaceae, Betulaceae, Lamiaceae, and species of *Zanthoxylum*, as well as *Acanthopanax setchuenensis*. The molecular structure of hesperidin includes an aglycone (either hesperetin or methyl eriodictyol) that is connected to rutinose and/or exists as a disaccharide. Thus, it can be categorized as a β -7-rutinoside of hesperetin. The amount of these composites in citrus fruits are influenced by factors such as the specific variety of the fruit, the part of the fruit being examined, environmental conditions, and the ripeness of the fruit (Imperatrice *et al.* 2022; Changae *et al.* 2023). The application of pesticides has markedly enhanced product quality. Nonetheless, the potential impacts on various essential organs remain largely uncharted, prompting researchers to explore and assess these adverse effects. Consequently, this study aimed to examine the potential effects and underlying mechanisms of chlorpyrifos disclosure on the liver and kidney. To achieve this, adult female mice were subjected to a continuous systemic administration of CPF. Afterward, hesperidin was formulated to deliver, and the study investigated its therapeutic efficacy in contradiction of oxidative stress, enzyme level, and tissue damage in mice treated with CPF.

MATERIALS AND METHODS

Hesperidin extraction

Citrus sinensis (orange) fruits were sourced from a local shop, afterward peeled and dried in a shaded area. Hesperidin extract was organized by the maceration method. The dried orange peels were saturated in a 10% potassium hydroxide solution overnight, followed by filtration of the mixture. After undergoing Soxhlet extraction and maceration, the filtrate's pH was adjusted to 3-4 with a 6% acetic acid solution. The concentrated solution was then refrigerated at 4-6 °C overnight, resulting in the formation of a solid crystalline substance. This mixture was filtered again, and the crude hesperidin was collected as an amorphous powder using a Buchner funnel (Sharifnia *et al.* 2023).

Experimental animals study design

Fifteen female adult Balb/C mice, weighing approximately 24 ± 2 g, were acquired for the study. The mice were conserved in a controlled environment adhering to established guidelines, with a room temperature of 22 ± 2 °C, a 14 light-10 dark cycle, and a relative humidity of 45-55%. They had continuous access to fresh water provided in polycarbonate bottles and were fed a diet of commercial rodent pellets. All procedures involving the mice were conducted in accordance with the guidelines for the care and use of laboratory animals (NIH Publications No. 8023, revised 1978) and were approved by the Institutional Animal Care and Use Committee, ensuring ethical treatment.

The mice were accidentally assigned to three groups, with five mice in each group:

Group 1: CPF (Model group) received CPF at a dosage of 3 mg kg⁻¹ for a duration of four weeks, administered intraperitoneally at a volume of 100 µL per mouse (Gheibi *et al.* 2020, 2023)

Group 2: The control group consisted of healthy mice that were administered DMSO via gavage at a dosage of 40 µL kg⁻¹ for 30 days.

Group 3: In the treatment group, following the induction of the model with CPF at a dose of 3 mg kg⁻¹ over 4 weeks, hesperidine was given at a dosage of 100 mg kg⁻¹ for 30 days (100 µL per mouse, via gavage; Sharifnia *et al.* 2024).

Oxidative stress assay

The sera were obtained for the evaluation of antioxidant enzyme activities. The activity of superoxide dismutase (SOD) was measured using a commercial assay kit that employs a colorimetric method at a wavelength of 420 nm.

Vital organ histopathology

The euthanasia of the mice was done using 10% Ketamine (250 mg kg⁻¹) and 2% xylazine (20 mg kg⁻¹). Subsequently, organs were meticulously dissected, and blood specimens were obtained through cardiac puncture. To process the tissue and enable its utilization for further applications in microtubes, the specimens were collected and preserved in a 10% formalin solution. Following the fixation of the samples through paraffin embedding, consecutive paraffin sections with a thickness ranging from 4-6 µm were equipped for staining with hematoxylin and eosin (Amanpour *et al.* 2024).

Evaluation of liver biomarkers

Following heart puncture to acquire blood samples, the concentrations of serum glutamic-oxaloacetic transaminase (SGOT), serum glutamic-pyruvic transaminase (SGPT), alkaline phosphatase (ALP), and BUN were calculated spectroscopically using commercial kits.

Statistical analysis

Data are presented as mean ± standard deviation (SD), and the graphs were created using Graph Pad Prism version 5.04. Statistical analysis was performed using analysis of variance (ANOVA), followed by a post-hoc Tukey test, with a *p*-value of less than 0.05 deemed significant for comparisons against the model group that received CPF without treatment. Asterisks indicate significant differences, with *: *p* < 0.05, **: *p* < 0.01, and ****: *p* < 0.001.

RESULTS

Oxidative stress assays

Following treatment, a noteworthy rise was observed in the SOD level of the CPF + Hesp group compared to CPF (*p* = 0.002), respectively. Additionally, a comparison CPF group with the control group revealed noteworthy alterations (*p* < 0.001).

Liver enzyme levels

The prescription of hesperidin caused a notable reduction in serum SGOT levels when compared to the CPF group (*p* < 0.001). Additionally, the serum SGPT levels in the hesperidin group were considerably lesser than those observed in the CPF group (*p* < 0.001). Furthermore, treatment with Hesperidin demonstrated a generally declining effect on ALP level relative to the CPF group (*p* < 0.001).

BUN concentration

As shown in Fig. 3, the level of sera BUN increased following CPF injection, but after treatment with hesperadin, the serum concentration statistically declined (*p* < 0.001). The comparison of the control and CPF groups exhibited the statistical significance in the two groups (*p* < 0.01).

Histopathological evaluation of liver and kidney tissues

Liver

As shown in Fig. 4, microscopic analysis of liver sections from the CPF-treated group revealed a notable increase in the percentage of vacuolated hepatocytes, characterized by indistinct nuclei and disrupted nuclear membranes, compared to other groups. Black arrows highlight additional pathological features such as hepatocellular

degeneration, inflammatory infiltration, and sinusoidal dilation. Furthermore, dead hepatocytes appeared less pigmented than viable ones, indicative of cytoplasmic degradation, with an estimated 50% tissue discoloration.

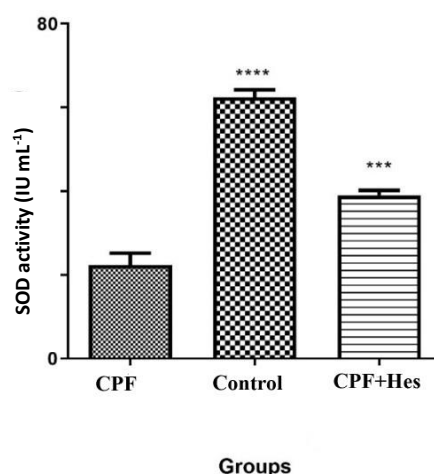


Fig. 1. Superoxide dismutase (SOD) activity was assessed in serum samples obtained from the CPF, Control, and CPF + Hesp groups. The data underwent statistical analysis using analysis of variance (ANOVA), followed by a post-hoc Tukey test. A *p*-value of less than 0.05 was deemed significant for comparisons with the model group that received CPF without any treatment. Significant differences are indicated by asterisks, with *: *p* < 0.05, **: *p* < 0.01, and ***: *p* < 0.001.

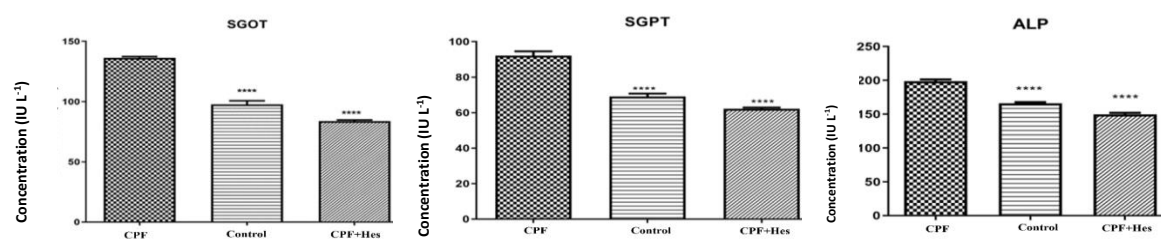


Fig. 2. illustrates the impact of CPF administration and hesperidin treatment on the serum levels of SGOT, SGPT, and ALP in the experimental mouse groups. The data is presented as a Mean \pm SD. A one-way ANOVA, accompanied by a post hoc LSD test, was employed for group comparisons. Significant differences are indicated by asterisks, with *: *p* < 0.05, **: *p* < 0.01, and ***: *p* < 0.001.

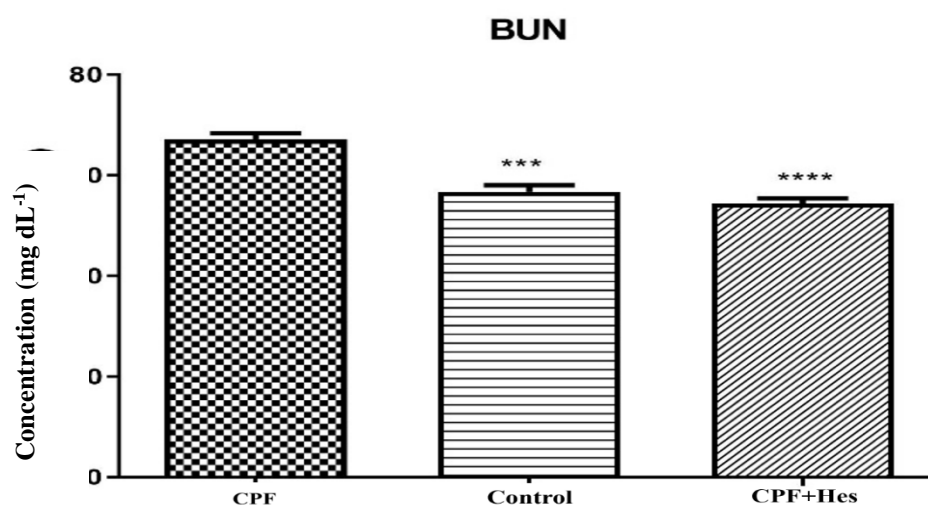


Fig. 3. The effects of CPF administration and treatment with Hesperidin on the serum level of BUN of mice in experimental groups. Data are represented as Mean \pm SD. One-way ANOVA followed by a post hoc LSD test was used for comparison between different groups. The asterisks replicate significant differences with *: *p* < 0.05, **: *p* < 0.01, and ***: *p* < 0.001.

Notably, accumulations of blood cells and lymphocytes were observed in areas vacated by necrotic cells, suggesting an active inflammatory response. In contrast, the control group exhibited normal hepatic architecture, with hepatocytes arranged radially around central veins and no signs of inflammation or degeneration. Conversely, liver sections from the hesperidin-treated group showed preserved hepatic morphology, with hepatocytes maintaining a normal appearance. A central vein with typical structure was observed in the interlobular spaces, along with a clearly defined portal triad between lobules. Kupffer cells were detected around the sinusoidal vessels, indicative of retained immune functionality. The liver inflammation score in the CPF+Hesp group was significantly lower than in the CPF group, reflecting the hepatoprotective effect of hesperidin. A small area with mild alteration is marked with a circle in the image, but overall histological features suggest substantial restoration of hepatic structure following hesperidin treatment.

Kidney

As shown in Fig. 4, kidney sections from the control group exhibited normal renal architecture, including well-formed glomeruli and renal tubules without evidence of pathology. In the cortical region, the number and size of glomeruli were appropriate, displaying uniform diameter and shape. Each glomerulus was surrounded by Bowman's capsule, composed of simple squamous cells with dark, elongated nuclei and uniform cytoplasm. The urinary space, located beneath Bowman's capsule, was regular in size and clearly visible. In contrast, kidney sections from the CPF-treated group showed marked structural alterations. These included reduced glomerular diameter, hyperemia, variation in glomerular size, and irregular spacing between structures. The urinary space appeared enlarged and distorted, and Bowman's capsule contained mesenchymal-like cells with small, irregular nuclei. Proximal convoluted tubules exhibited indistinct lumens and atrophic epithelial cells, while distal tubules contained few short cells with dark nuclei and pale cytoplasm. In addition, hyperemia and vasodilation were evident in intertubular and intraglomerular spaces. Black arrowheads indicate damaged renal tubules, epithelial desquamation, and possible inflammatory infiltration, confirming CPF-induced nephrotoxicity. In the hesperidin-treated group, kidney sections displayed milder histological changes and restored renal organization. Some glomeruli exhibited slight reductions in size and mild shrinkage, resulting in a relative increase in urinary space. Bowman's capsule appeared normal, with broad, elongated cells and regular nuclei. Proximal tubules showed minimal cytoplasmic and nuclear discoloration, and distal tubules had wide lumens and mildly atypical cytoplasm. Slight hyperemia was observed in intraglomerular and interstitial areas, but overall findings indicate that hesperidin exerted a nephroprotective effect by attenuating CPF-induced damage.

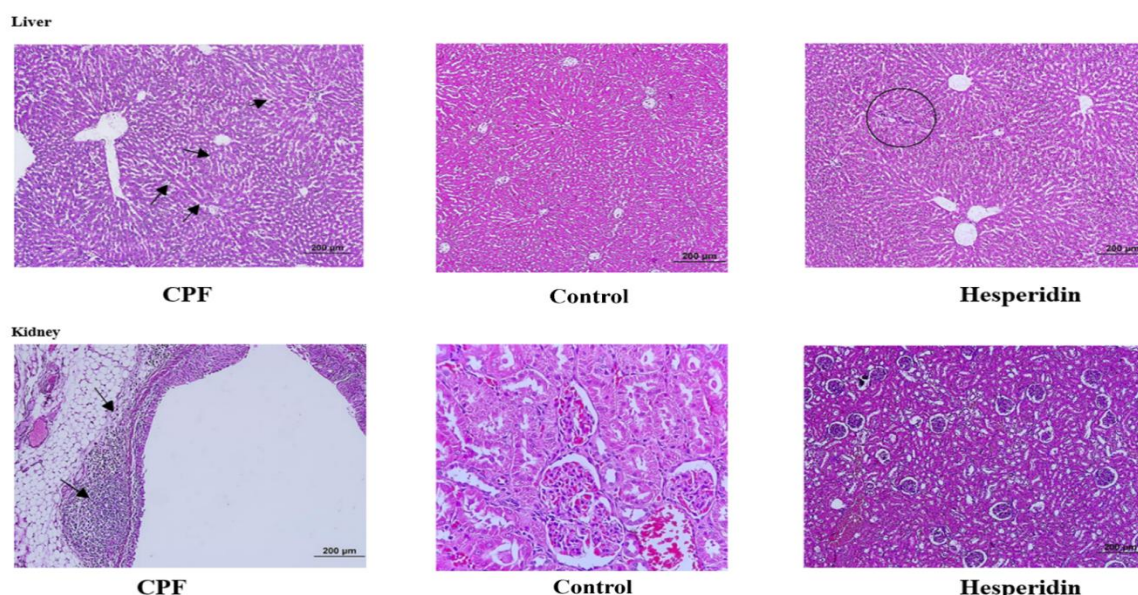


Fig. 4. The effects of CPF administration and treatment with hesperidin on light microscopy (LM) images of liver and kidney tissues, hematoxylin, and eosin (H & E) staining of experimental groups. Liver: In the CPF-treated group, marked hepatocellular degeneration, sinusoidal dilation, and inflammatory cell infiltration are evident (black arrows), indicating hepatotoxicity. The control group displays normal hepatic architecture with intact central veins and regularly arranged hepatocytes. The hesperidin-treated group shows largely preserved liver structure with minimal changes (highlighted by a circle), suggesting a protective effect of hesperidin against CPF-induced liver damage. Kidney: The CPF-treated group exhibits

signs of nephrotoxicity, including tubular degeneration, epithelial desquamation, and possible inflammatory infiltration (arrowheads). The control group shows normal renal histology, with well-preserved glomeruli and tubules. In the hesperidin group, kidney tissue architecture appears largely restored with reduced histopathological alterations, indicating the nephroprotective effect of hesperidin.

DISCUSSION

The administration of hesperadin reduced the toxic effects of chlorpyrifos (CPF), as evidenced by histopathological assessments of key organs. Lower inflammatory scores, decreased enzyme levels, and enhanced SOD concentrations characterized this reduction. In contemporary research, using plant-derived natural antioxidants has garnered significant interest. Hesperidin is a well-known natural antioxidant celebrated for its wide range of medicinal benefits, which encompass anti-inflammatory, wound-healing, and protective effects on the liver and nervous system. The compound 2-methoxy-4-vinylphenol hesperidin is an innovative combination of 2-methoxy-4-vinylphenol, a naturally occurring phenolic compound found in various plants, and hesperidin, a flavanone glycoside commonly found in citrus fruits, making up about 17.17% (Küçükler *et al.* 2021). In 2006, Cho conducted an evaluation of the antioxidant and neuroprotective effects of hesperidin using rat cortical cells culture. Hesperidin was recognized as a potent antioxidant, demonstrating a significant ability to inhibit lipid peroxidation in rat brains (Cho 2006). Supporting these findings, hesperidin was shown to protect primary cultured cortical cells from oxidative neuronal damage caused by H₂O₂ or xanthine. Additionally, it was found to alleviate excitotoxic neuronal injury resulting from excessive glutamate exposure in cortical cultures. The combined findings emphasize the significant antioxidant and neuroprotective effects of hesperidin, suggesting its probable to safeguard neurons against several challenges linked to a variety of neurodegenerative disorders (Sharma S *et al.* 2022). Due to its wide array of pharmacological effects, hesperidin is regarded as one of the greatest fascinating and potentially advantageous bioflavonoids. Citrus fruits and their juices are extensively consumed around the world, providing easily accessible dietary sources. Moreover, the processing of citrus by-products generates a significant amount of hesperidin, primarily from the enormous quantities of peel produced. Utilizing these by-products could lead to the creation of novel nutraceuticals or the enhancement of existing products (Imperatrice *et al.* 2022). The biological activities associated with hesperidin encompass immunomodulatory effects, antidepressant properties, antiallergic actions, ultraviolet protection, platelet aggregation inhibition, and wound healing potential. In addition to these functions, hesperidin demonstrates substantial neuroprotective effects in numerous neurodegenerative diseases (Wafqan HM *et al.* 2022; Ayomide *et al.* 2023). Recent studies have revealed that the antioxidant capabilities of Hsd/Hst surpass simple radical scavenging, as they also bolster cellular antioxidant defenses (Parhiz *et al.* 2015). In humans, assessing specific immunotoxic effects linked to organophosphates (OPs) is complicated by repeated exposure to immunomodulatory contaminants. However, existing scientific literature indicates that OPs do exhibit immunotoxic properties. Specifically, OPs have the capacity to influence neutrophil-mediated immune responses, as observed in individuals with occupational exposure. Metabolites of the pesticide malathion have been found to trigger histamine release in human basophilic cells. Studies indicate that dimethoate and chlorpyrifos can modify the levels of pro-inflammatory cytokines while concurrently reducing the levels of the IL-10. These compounds also influence the Akt and ERK signaling pathways in dendritic cells exposed to OPs. Moreover, it has been observed that OP exposure can inhibit the production of interferon-beta (IFN- β) in macrophages (Camacho-Pérez *et al.* 2022). Toxin administration resulted in a significant reduction of superoxide dismutase (SOD) activity in murine subjects. SOD serves as a crucial component of the innate defense mechanism against oxidative stress by facilitating the conversion of superoxide radicals into hydrogen peroxide, which is subsequently detoxified by enzymes such as glutathione peroxidase or catalase. As a result, SOD plays a vital role in mitigating the formation of highly reactive reactive oxygen species (ROS), including peroxynitrite and hydroxyl radicals (Kumar *et al.* 2021). The findings of the present examination revealed an elevation in malondialdehyde (MDA) levels alongside a reduction in SOD activity within the chlorpyrifos group when compared to the control group. Both hesperidin and niosomal hesperidin were effective in lowering MDA concentrations and enhancing SOD activity. Notably, there was no significant alteration in the ability of hesperidin and liposomal hesperidin to regulate MDA levels. However, liposomal hesperidin exhibited a more pronounced effect in augmenting SOD activity (Sharifnia *et al.* 2023). In a controlled experimental investigation, forty adult female bulb/c mice were divided into four separate groups: one receiving hesperidin, another receiving malathion, a third group receiving both malathion and hesperidin, and a control group. After a continuous treatment duration of 35 days, the results revealed that malathion exposure caused significant structural

and architectural disruptions in the ovarian tissues. The malathion treatment was associated with a decrease in follicle counts at all developmental stages with declined serum levels of sex hormones and SOD. Importantly, hesperidin was effective in counteracting malathion's detrimental effects across all aforementioned parameters. The administration of hesperidin enhanced the expression of PCNA and FSHR proteins and activated antioxidant defenses, thereby alleviating the undesirable influences of malathion on ovarian tissues (Talebi *et al.* 2024). The CPF affects significant histopathological alterations in the liver due to increased fabrication of reactive oxygen species (ROS). Consequently, liver samples from the CPF control group displayed marked venous congestion, localized necrosis of hepatocytes, disruption of the hepatic cord structure, and infiltration by inflammatory cells. Hesperidin has demonstrated hepatoprotective properties by plummeting oxidative stress, improving antioxidant capacity, and possessing anti-inflammatory properties. It is acknowledged for its diverse pharmacological effects, positioning it as one of the most promising and beneficial bioflavonoids. Numerous commercially available supplements feature hesperidin, either alone or in combination with other bioflavonoids derived from citrus. Additionally, the processing of citrus by-products generates a significant amount of hesperidin, primarily from the large quantities of peel produced. Utilizing these by-products could lead to the creation of new nutraceuticals or the improvement of existing products.

CONCLUSION

The article concludes by emphasizing that hesperidin may offer protective benefits against the harmful effects of chlorpyrifos, highlighting the need for further in-depth studies and rigorous research to clarify the mechanisms through which hesperidin provides its protective effects. It also calls for a comprehensive investigation into the broader health benefits associated with hesperidin for individuals exposed to such toxic substances. Moreover, hesperidin and extracts from citrus fruit peels may exhibit antioxidant properties with diverse therapeutic applications. Continued research is essential to develop innovative pharmaceuticals from this natural resource.

ACKNOWLEDGEMENTS

All experimental study carried out in a private laboratory located in Tashkent, Uzbekistan and the study is self-funded.

REFERENCES

- Amanpour, P, Eftekhari, Z, Eidi, A & Khodarahmi, P 2024, Ameliorative mechanism of dietary vitamin d and magnesium on newborn's pulmonary toxicity induced by cadmium. *Journal of Trace Elements in Medicine and Biology: Organ of the Society for Minerals and Trace Elements (GMS)*, 84: 127469.
- Ayomide Victor Atoki Patrick Maduabuchi Aja, TSSENO & Awuchi, CG 2023, Hesperidin plays beneficial roles in disorders associated with the central nervous system: A review. *International Journal of Food Properties*, 26(1): 1867-1884.
- Barzi, NV, Eftekhari, Z, Doroud, D & Eidi, A 2020, DNA methylation changes of apoptotic genes in organogenesis stage of mice embryos by maternal chlorpyrifos induction. *Environmental Toxicology*, 35(7): 794-803.
- Blain, PG 2011, Organophosphorus poisoning (acute). *BMJ Clinical Evidence*, 2011, England.
- Camacho-Pérez, MR, Covantes-Rosales, CE, Toledo-Ibarra, GA, Mercado-Salgado, U, Ponce-Regalado, MD, Díaz-Resendiz, KJG & Girón-Pérez, MI 2022, Organophosphorus pesticides as modulating substances of inflammation through the cholinergic pathway. *International Journal of Molecular Sciences*, 23(9).
- Changae F, Goudarzi MA, Ghobadi R, Parsaei P 2023, Antioxidant effects of methanolic extracts of *Anthemis susiana* Nabelek, *Alyssum campestre*, and *Gundelia tournefortii*. *Caspian Journal of Environmental Sciences*, pp.1-6.
- Cho, J 2006, Antioxidant and neuroprotective effects of Hesperidin and its aglycone hesperetin. *Archives of Pharmacol Research*, 29(8): 699–706.
- Gheibi, P, Eftekhari, Z, Doroud, D & Parivar, K 2023, Association between uterine toxicity induced by chlorpyrifos and downregulation of heparin-binding epidermal growth factor and L-selectin genes. *Veterinary Research Forum: an International Quarterly Journal*, 14(1): 45–52.
- Gheibi, P, Eftekhari, Z, Doroud, D & Parivar, K 2020, Chlorpyrifos effects on integrin alpha v and beta 3 in implantation window phase. *Environmental Science and Pollution Research*, 27: 29530–29538.
- Imperatrice, M, Cuijpers, I, Troost, FJ & Sthijns, MM 2022, Hesperidin functions as an ergogenic aid by increasing endothelial function and decreasing exercise-induced oxidative stress and inflammation, thereby contributing to improved exercise performance. *Nutrients*, 14(14): 2955.

- Kermani, M, Dowlati, M, Gholami, M, Sobhi, HR, Azari, A, Esrafil, A, Yeganeh, M & Ghaffari, HR 2021, A global systematic review, meta-analysis and health risk assessment on the quantity of Malathion, Diazinon and Chlorpyrifos in Vegetables. *Chemosphere*, 270: 129382.
- Küçükler, S, Çomaklı, S, Özdemir, S, Çağlayan, C & Kandemir, FM 2021, Hesperidin protects against the chlorpyrifos-induced chronic hepato-renal toxicity in rats associated with oxidative stress, inflammation, apoptosis, autophagy, and up-regulation of PARP-1/VEGF. *Environmental Toxicology*, 36(8): 1600-1617.
- Kaur L, Kumar Sharma M 2025, Heavy metals pollution and health risk assessment of groundwater of Bikaner Block (Rajasthan). *Journal of Chemical Health Risk*, 15: 111-113.
- Kumar, A, Siddiqi, NJ, Alrashood, ST, Khan, HA, Dubey, A & Sharma, B 2021, Protective effect of eugenol on hepatic inflammation and oxidative stress induced by cadmium in male rats. *Biomedicine & Pharmacotherapy = Biomedecine & Pharmacotherapie*, 139: 111588.
- Mansukhani, M, Roy, P, Ganguli, N, Majumdar, S & Sharma, S 2024, Organophosphate pesticide chlorpyrifos and its metabolite 3,5,6-trichloropyridinol downregulate the expression of genes essential for spermatogenesis in caprine testes. *Pesticide Biochemistry and Physiology*, 204:106065.
- Nandi, NK, Vyas, A, Akhtar, MJ & Kumar, B 2022, The growing concern of chlorpyrifos exposures on human and environmental health. *Pesticide Biochemistry and Physiology*, 185: 105138.
- Parhiz, H, Roohbakhsh, A, Soltani, F, Rezaee, R & Iranshahi, M 2015, Antioxidant and anti-inflammatory properties of the citrus flavonoids Hesperidin and hesperetin: an updated review of their molecular mechanisms and experimental models. *Phytotherapy Research*: 29(3): 323–331.
- Pyrzynska, K 2022, Hesperidin: A Review on Extraction Methods, Stability and Biological Activities. *Nutrients*, 14(12): 2387.
- Sharifnia, M, Eftekhari, Z & Mortazavi, P 2023, Niosomal Hesperidin attenuates the M1/M2-macrophage polarization-based hepatotoxicity followed chlorpyrifos-induced toxicities in mice. *Pesticide Biochemistry and Physiology*, 105724.
- Sharifnia, M, Eftekhari, Z & Mortazavi, P 2024, Niosomal hesperidin attenuates the M1/M2-macrophage polarization-based hepatotoxicity followed chlorpyrifos-induced toxicities in mice. *Pesticide Biochemistry and Physiology*, 198: 105724.
- Sharma S, A, N, V, Kar, B, Das, U & Paira, P 2022, Target-specific mononuclear and binuclear rhenium (i) tricarbonyl complexes as upcoming anticancer drugs. *RSC Advances*, 12(31): 20264–20295.
- Talebi, S, Kooshki, A, Zarein, M, Seify, M, Dolatshahi, B, Shoorei, H & Bhandari, R 2024, Protective effect of Hesperidin on malathion-induced ovarian toxicity in mice: The role of miRNAs, inflammation, and apoptosis. *Toxicology Reports*, 12.
- Vahabi Barzi, N, Eftekhari, Z, Doroud, D & Eidi, A 2022, Maternal exposure during organogenesis to chlorpyrifos insecticide induce apoptosis process. *The Journal of Maternal-Fetal & Neonatal Medicine: The Official Journal of the European Association of Perinatal Medicine, the Federation of Asia and Oceania Perinatal Societies, the International Society of Perinatal Obstetricians*, 35(20): 3845–3852.
- Wafqan HM, Almoussawi ZA, Karim NA, Alghazali T, Abd Alhasan SA, Al-Muttar MY, Hakki M 2022, How the government and private sectors in Egypt contribute to the country's environmental issues (An environmental economic approach). *Caspian Journal of Environmental Sciences*, 20(5): 977-984.
- Yönden, Z, Shabestari, AM, Ghayourvahdat, A, Azimizonuzi, H, Hosseini, ST & Daemi, A 2022, How anti-inflammatory and antioxidant dietary supplements are effective in undermining COVID-19 pathogenesis: The role of vitamin C and D. *Medicina Balear*, 37:158-164.
- Zhong, G, Xie, Z, Cai, M, Möller, A, Sturm, R, Tang, J, Zhang, G, He, J & Ebinghaus, R 2012, Distribution and air-sea exchange of current-use pesticides (CUPs) from East Asia to the high Arctic Ocean. *Environmental Science & Technology*, 46: 259-267.

Bibliographic information of this paper for citing:

Rizaeva, MJ, Ayapov, SB, Akhmedov, J, Rajabov, O, Dilmuradova, KR, Saidkarimova, MI, Mulhamedova, MS, Ikramova, M, Gudalov, M, Shernazarov, FH 2025, Evaluation of mice's liver and kidney alterations caused by CPF with consumption of hesperidin. *Caspian Journal of Environmental Sciences*, 23: 587-594.
